

RESEARCH ARTICLE

Retinal Image Processing on Early Glaucoma Detection

H. Sahana^{1*} • Dr. Archana Nandibewor² • Dr. Aijazahamed Qazi³
• Dr. Pushpalatha S Nikkam⁴

¹M. Tech, Department of CSE, SDMCET Dharwad, India.

²Assistant Professor, Department of CSE, SDMCET Dharwad, India.

³Assistant Professor, Department of CSE, SDMCET Dharwad, India.

⁴Assistant Professor, Department of ISE, SDMCET Dharwad, India.

ARTICLE INFO

Article History:

Received: 28.01.2021

Accepted: 20.02.2021

Available Online: 08.04.2021

Keywords:

Glaucoma

Fundus Image

MATLAB

Intraocular Pressure

ABSTRACT

Glaucoma is a habitual eye disorder which harms eye's second cranial nerve. There are millions of second cranial nerves. The main function of these types of nerves is to sending captured visual information from retina to the brain. The escalate pressure in the human eye leads to Glaucoma. This heavy pressure is known as intraocular pressure. This heavy pressure leads to damage eye's optic nerve head and retina continuously further it tends to vision loss. In this paper there are two datasets including both normal person and affected person's eye color images. The principal aim of this project is to compare the color of the eye with these two datasets. A special camera which is attached to less power microscope is called fundus camera or retinal camera. The images captured by this type of fundus camera is called fundus picture[1]. It is a high dimensional laser image. MATLAB software tool is used to fulfill the feature extraction of these fundus images. A color pixel in the affected area of the person is measured to check whether a person is Glaucomatous or not. If the final result is positive then it is Glaucoma.

Please cite this paper as follows:

Sahana, H., Nandibewor, A., Qazi, A. and Nikkam, P.S. (2021). Retinal Image Processing on Early Glaucoma Detection. *Alinteri Journal of Agriculture Sciences*, 36(1): 138-141. doi: 10.47059/alinteri/V3611/AJAS21020

Introduction

Glaucoma is an eye disorder in which the vision of the eye gets progressively damaged. The eye is filled with the fluid called aqueous humour. This fluid persistently generate and flows out of the eye. If this fluid fails to flow out leads to increase in pressure. Elevated fluid compulsion in the eye is the major cause to harm the optic nerve which leads to Glaucoma. This compulsion is called as intraocular pressure[2][3]. Eye tends to vision loss due to less interaction between retina and brain.

GLAUCOMA

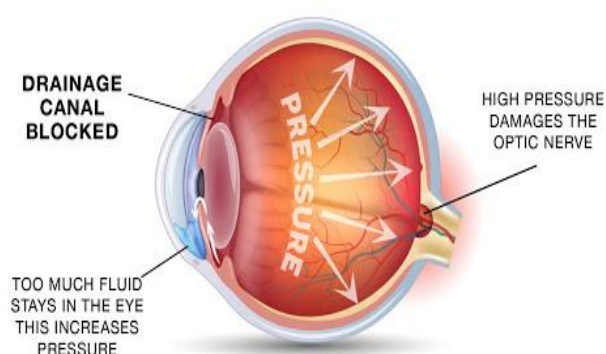


Fig. 1. Glaucoma Eye image

* Corresponding author: H. Sahana

1. Working of the Proffered System

This developed system represents glaucoma disorder in early stage. We know that glaucoma is the second leading disease in word which cause permanent vision loss. The purpose of algorithm is to identify the perfect position of the eye's fore chamber region for the angle computation precisely. It is possible to identify glaucoma in starting stages for diagnosis of the eye, the obtained angle is checked to confirm an eye is affected by glaucoma or no.

2. Categories of Glaucoma

There are so many varieties of glaucoma. Primary and most common types of glaucoma are described in this paper[4].

a. Primary Open-Angle Glaucoma

Open-angle glaucoma is also called habitual glaucoma. The angle between the cornea and iris meets is spacious. It is called as Primary open angle glaucoma. It is caused due to partially blocked drainage system of the eye which causes pressure to build within the eye[4].

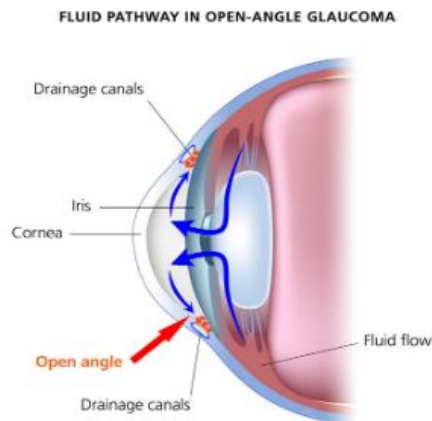


Fig. 2. Open Angle Glaucoma

b. Angle-Closure Glaucoma

Angle-closure glaucoma, a uncommon form of glaucoma. It is also called acute glaucoma or narrow-angle glaucoma.

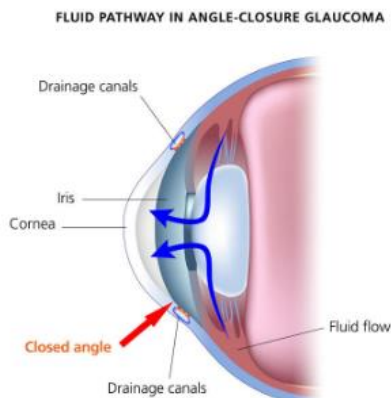


Fig. 3. Angle Closure Glaucoma

There is a closed angle between the cornea and iris meets. Complete blockage of drainage system results in angle closure glaucoma. It develops very quickly [4].

c. Normal-Tension Glaucoma

It is also called low-stress or normal-compulsion glaucoma. In this category of glaucoma the optic nerve is injured even though there is less intraocular pressure[5].

d. Congenital Glaucoma

Congenital glaucoma occurs in toddler or youth. It is routinely diagnosed within one year of babies. The improper evolution of drainage system of babies eyes leads to congenital glaucoma[5].

Methodology

Fundus images collected from the fundus camera or retinal camera is used for testing. The retinal images are detected, diagnosed, and prevention of hazards correlated with this disorder. Pre-processing approaches have been applied to the image and, depending upon the approaches, various classifiers have been used to recognise glaucoma[6].

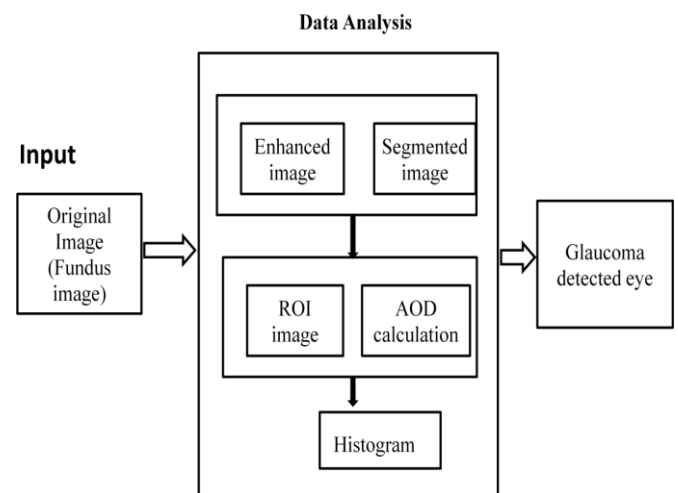


Fig. 4. Architectural diagram of Glaucoma

Digital Fundus Images

This section describes about how to improve the disparity pledge and clearness of the digital fundus images of the eye in regulate to make a picture fit for effective anterior chamber segmentation[7].

Enhancement of Image

The histogram equalization technique is used to acquire a latest image with a homogeneous histogram[8].

Thresholding and Binarization

Thresholding of an image is a simplest technique of segmenting an image. Binary images are produced from a grayscale images. It produces white and black pixels according to image intensity. If the image intensity is greater than some threshold or constant it produces "white

or background" pixels else "black or object" pixel[8]. Binarization is a method used to convert grayscale image into two essential images that is black and white images.[9].

Region Classification Method

The ROI of digital fundus image found are classified. All of these images are classified as (R) and their properties stored in MATLAB functionality. In case, R equal to 1 to indicate to region 1;the R equal to 2 indicates the region 2;and so on.

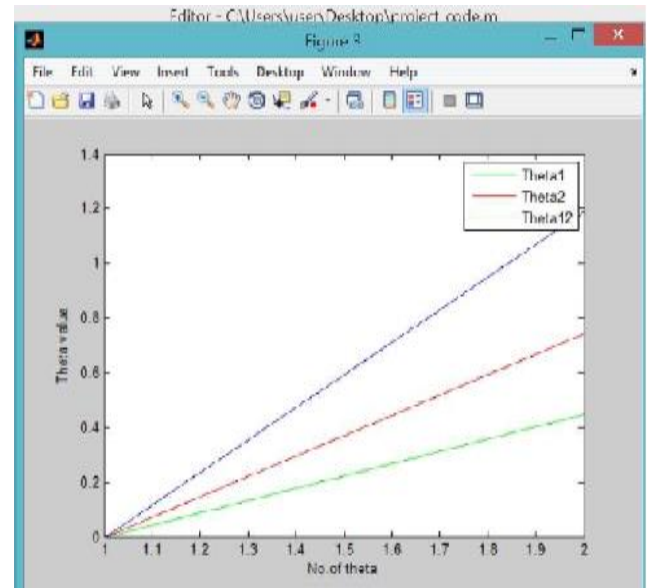
AOD (Aerosol Optical Depth) Calculation

According to theory of digital fundus images resolution it is well known that distance between 2 elements pixels is about equal to 19.5-20 micrometer.

Let the two angle be Theta1 and Theta2.The effective angle will be calculated as : $\text{Theta} = \text{Theta1} + \text{Theta2}$

Results and Discussion

The system aim to improve the disparity motion and clearness of the particular digital fundus image to produce the image burst for accurate anterior chamber segmentation for angle computation. If the image intensity is greater than some threshold or constant it produces "background" pixels else "object" pixel. For systematic and structured anterior chamber categorization, segmentation and computation, two fundamental operations in mathematical morphology such as dilation and erosion are used to develop perfect image. After performing enhancement, detection process is executed to detect the Glaucoma in Eye. Both glaucoma patient and doctor can analyse the status of each and every examination. And the recovery chart or graphical depiction of his/her report may be given to the patient. Fig 5. (a) AOD (Aerosol Optical Depth) calculation of Glaucoma eye. (b) AOD (Aerosol Optical Depth) calculation of normal eye. If the result of the Theta12 value is greater than some threshold value then it is glaucomatous. Pharmaceutical and Incision is possible in case of person affected from glaucoma. Research of this project is still in progress.



(b)

Fig. 5. (a) AOD (Aerosol Optical Depth) calculation of Glaucoma eye. (b) AOD (Aerosol Optical Depth) calculation of normal eye

Conclusions

We all know that glaucoma is a disorder. This can be caused due to pressure in the eye's optic nerve increases more than the threshold value. The main motivation behind the project is to make better understanding the awareness of glaucoma at an early stage. The project developed can be handy so that only few people can use it. Overall the proposed system helps any user to clearly understand the disease of eye. The academic goal of this project is to develop the research, MATLAB programming and analysis. Detecting glaucoma in its early stage remains threat, because bulk of glaucoma cases are not identified in neighborhood. Diagnosis of glaucoma in prior stage is necessary for bloat the aid surgery of patients as well as to lessen the economic significance of glaucoma in community.

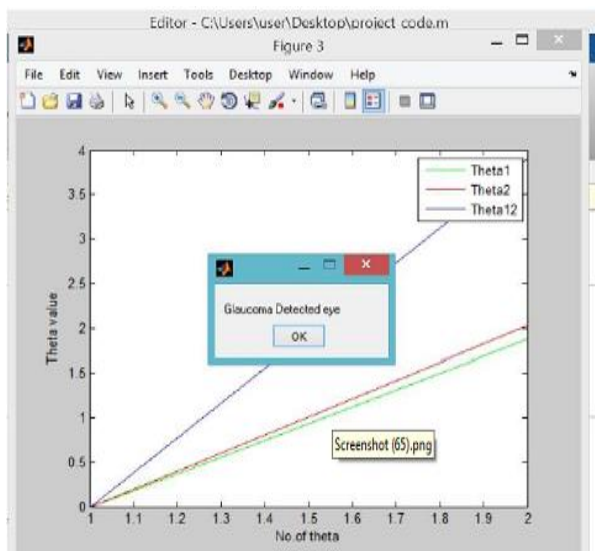
Future Scope

There are three possible future works may be added. Those task are given below.

1. The proposed system can also implement using neural network.
2. Can make use different classifier for similar implementation.
3. Training of the Theta values and L values can be done for automatic detection.
4. The system can be added to cloud for a faster access.

Acknowledgments

Foremost, I would like to express my gratitude to DR.K. GOPINATH, Principal, and the Management, S.D.M College of Engineering and Technology, Dharwad, Karnataka, India. I sincerely express my deep sense of gratitude to Dr. Archana Nandibewor for guiding me in every stage of this research. I would like extend my special thank to SDM Medical College



(a)

who have helped me in issuing fundus images for this research.

References

- Byahatti, A.N.S., Sridevi, K., and Hegadi, R. (2014). Computer based diagnosis of glaucoma using digital fundus images. *In Proceedings of the World Congress on Engineering*, 3: 3-5.
- <https://www.aao.org/eye-health/diseases/what-is-glaucoma>
- <https://en.wikipedia.org/wiki/Glaucoma>
- <https://www.webmd.com/eye-health/glaucoma-eyes#2>
- <https://www.glaucoma.org/glaucoma/types-of-glaucoma.php>
- Qureshi, I. (2015). Glaucoma detection in retinal images using image processing techniques: a survey. *International Journal of Advanced Networking and Applications*, 7(2): 2705- 2718.
- Kawde, M.M., and Bairagi, V.K. (2016). Early detection of glaucoma disease using image processing. *Indian Journal of Science and Technology*, 9: 30.
- [https://en.wikipedia.org/wiki/Thresholding_\(image_processing\)](https://en.wikipedia.org/wiki/Thresholding_(image_processing))
- <https://craftofcoding.wordpress.com/2017/02/13/image-binarization-1-introduction/>