

RESEARCH ARTICLE

Seroepidemiological and Clinicopathological Study of Feline Coronavirus (FCoV) and Feline Infectious Peritonitis (FIP), Could Guide to SARS-CoV-2 (COVID-19) in ‘One Health’ Approach

Bilge Kaan Tekelioglu^{1*}

^{1*}Çukurova University, Ceyhan Veterinary Medicine, Department of Virology, Adana/Turkey.

ARTICLE INFO

Article History:
Received: 10.08.2020
Accepted: 02.09.2020
Available Online: 29.12.2020

Keywords:

Feline Coronavirus
Feline Infectious Peritonitis
Seroepidemiology
Clinicopathology
SARS CoV-2
COVID-19

ABSTRACT

Feline coronavirus 176 seropositive cats were examined in 2014-2019. Seroepidemiological, serological, clinical, haematological and biochemical data were analysed with IBM-SPSS Statistics. Clinicopathological signs were typical with enteric form in 125 cats (71%) and FIPV in 51 cats (29%). Fever, depression, dullness, weight loss, vomitus, growth retardation, diarrhoea, ocular and neurological symptoms were findings. 40 cats (23%) were died, 17 had pleural effusion, 19 had ascites, and 16 Rivalta tests were positive. Post-mortem FIP confirmation was at 8 cats. Of the FCoV seropositive cats, 22 (12.5%) had FIV antibodies, 7 (3.9%) were positive for FLV antigens, 2 (1.1%) were positive for FCoV, FIV and FLV, and 2 (1.1%) were FmopV RNA positive. FCoV, canine enteric CoV, human CoV-229E and CoV-NL63 belong to Alphacoronavirus, and canine respiratory CoV, Human CoV-OC43, CoV-HKU1, SARS, MERS and COVID-19 belong to Betacoronavirus genus, originated from bat gene pool and is of animal origin cause zoonotic infections. Covid-19 pathogenesis is not fully understood and data's focused on case fatality rates. Covid-19 was reported as anthrozoosis infecting cats, dogs, tigers and lions. The panthropism risk should be investigated. In particular, the clinicopathology and treatment modalities of feline coronavirus and COVID-19 infections are having similarities such as GS-441524 as the main metabolite of remdesivir prodrug and dexamethazone responses, and both can cause resident and persistent infections in many organs, including the eyes and brain, of varying severity. The obtained data have been evaluated in the 'One Health' approach to better understand the aetiology, pathogenesis and clinicopathology of coronavirus infections, and presenting valuable findings to help the control of COVID-19 epidemic. Veterinary medicine will help to multidisciplinary collaboration to develop effective vaccines and drugs with many years of coronavirus experiences.

Please cite this paper as follows:

Bilge Kaan Tekelioglu. (2020). Seroepidemiological and Clinicopathological Study of Feline Coronavirus (FCoV) and Feline Infectious Peritonitis (FIP), Could Guide to SARS-CoV-2 (COVID-19) in ‘One Health’ Approach. *Alinteri Journal of Agriculture Sciences*, 35(2): 181-196. doi: 10.47059/alinteri/V35I2/AJAS20092

Introduction

Coronaviruses (CoVs) are group of enveloped, single-stranded, positive-sense RNA viruses belong to the family of *Coronaviridae* from *Nidovirales* order and cause various viral diseases by club-like surface spikes in mammals, avian and humans. The genera of CoVs are classified as *Alphacoronavirus*, *Betacoronavirus*, *Gammacoronavirus* and *Delta coronavirus*, and bats, birds and rodents are known natural reservoirs. CoVs have the ability to cause different severity infections in the range of increased virulence,

multiple tissues and organ tropism and extended host range with the emergence of new viral strains due to genetic variations suitable for mutations and recombination. (Lai and Holmes, 2001; Lau et al., 2012; Susanna et al., 2015). Coronaviral infections are ranging from enteritis to severe fatal diseases in felids, canids, bovids and upper respiratory disease in avian and humans (Myrrha et al., 2011; Tekelioglu et al., 2015; NIAID, 2020; WHO, 2020; Yanga et al., 2020).

Feline coronaviruses classified in “subgroup1a” and consist of two biotypes designated as *feline enteric coronavirus* (FECV) and *feline infectious peritonitis virus* (FIPV), which are both divided into serotype I and II (Addie et al., 2003; Li et al., 2018; Jaimes et al., 2020). The feline

* Corresponding author: ktekelioglu@cu.edu.tr

originated serotype-I is difficult to grow in cell culture. Serotype-II arose from the recombination of FCoV serotype I with *canine coronavirus* (CCoV) and grows rapidly in cell culture with a lytic cytopathic effect (Pedersen et al., 2009; Lauzi et al., 2020). The formation of different viral populations infected with FECV and FIPV may cause FIP as well as an internal mutation in cats can lead to the emergence of FIPV (Addie et al., 2003; Brown et al., 2009; Jaimes et al., 2020). The virus remains in fomites for 3-7 weeks, and transmission occurs by the fecal-oral route (Pedersen et al., 2009; Kipar et al., 2010). FCoVs primarily infect enterocytes and spread from the intestine by monocyte-associated viremia (Straineri et al., 2018). Replication of monocytes and macrophages has also been reported in healthy cats. (Felten et al., 2017). Continuously or transient virus shedding may occur by persistent infected, asymptomatic cats for a period of months or years. (Addie et al., 2009; Kipar et al., 2010). The symptoms are highly variable and most infected cats stay healthy with the exception of mild enteritis (Hoskins, 1993; Pedersen, 2014; Tekelioglu et al., 2015). *Feline infectious peritonitis* (FIP) is the fatal form and developed in cats up to 12% and mainly occurs in young cats between 3 to 16 months of age associated with stress, immunity and multi-cat households (Addie et al., 2009; Vogel et al., 2010). The effusive (wet) form (polyserositis and vasculitis) and non-effusive (dry) form (pyogranulomatous lesions in organs) of FIP are well documented. Ascites and pleural effusions, fever refractory to antibiotics, weight loss, anorexia and lethargy are the most prominent clinical signs of effusive (wet) form (Addie et al., 2009; Pedersen, 2014; Tekelioglu and Haligur, 2016). The definitive and differential diagnosis of FCoV and FIP is complicated and depending on comprehensive examinations based on history, serology, haematology, molecular and post mortem analyses. Haematological and biochemical changes are not very specific and serological tests may fail to detect the active infection (Sharif et al., 2010; Tekelioglu et al., 2015; Soma et al., 2018; Stranieri et al., 2018). Polymerase chain reaction (PCR) can be used to examine abdominal, pleural and aspiration fluid and biopsied tissue (Sharif et al., 2010; Emmler et al., 2019; Lorusso et al., 2019; Myrrha et al., 2019). FCoV immunofluorescent antibody (IFA) test declared as the gold standard method (Addie et al., 2004; Pratelli, 2008). The prevalence of FCoV can rise up to 90% in multi-cat environments and 60% in house-hold cats early detection at early stage can be useful to minimize the spread of virus in a cat population (Addie et al., 2009; Sharif et al., 2010).

Coronaviruses have high zoonosis potentials which can be transmitted between animals and humans, such as Severe Acute Respiratory Syndrome (SARS-CoV) were transmitted from civet cats to humans and Middle East Respiratory Syndrome (MERS-CoV) from dromedary camels to humans. The well known SARS-CoV has been observed since November 2002 and MERS-CoV September 2012. Upon the current findings, there are different coronaviruses that cause infections in different animals that do not cause infection in humans yet (Cheng et al., 2007; Menachery et al., 2015; Ramadan et al., 2019; NIAID, 2020, WHO, 2020) reported an infectious potential of a SARS-like virus

(SHC014- CoV), which was currently circulating in Chinese horseshoe bat populations. At December 2019, a new strain was discovered and named as Coronavirus disease (COVID-19) which has not been previously identified in humans. Researches indicated Covid-19, MERS-CoV and SARS-CoV were originated in bats. Common signs are including fever, respiratory illness symptoms, cough, shortness of breath and breathing difficulties. The infection may cause severe acute respiratory syndrome, pneumonia, kidney failure, ocular and neurological signs and even death in more severe cases.

This study is based on the 5 years data analyses of 176 FCoV seropositive cats. The epidemiological data, serological status, clinical signs, laboratory results were statistically analyzed to make a seroepidemiological and clinicopathological investigation of feline coronavirus infections. In the differential diagnosis, following an algorithm that includes patient history, clinical findings, habitat information, serological tests and laboratory findings is a recommended requirement. COVID-19 is a zoonotic infection and, on the contrary, caused anthrozoosis in cats, dogs, tigers and lions. The data are not yet sufficient to confirm that there is a risk of pantropism, but it is an important issue needs to be carefully and thoroughly investigated as a preventive action on potential risk to public health. Results were compared with COVID-19 published reports from 'One Health' perspectives to help a better understanding of the virus and the disease. No vaccine or antiviral medication is yet available to prevent or treat human coronavirus infections. Veterinary medicine could guide to human medicine in future researches with its precious and long-lasting CoVs experiences on the control of the infection, development of safe vaccines and therapeutic antiviral drugs.

Materials and Methods

Study Population and Sampling

176 ill cats with in Adana and Istanbul city with compatible symptoms of viral infections and serologically positive to FCoV were included in the study population between May 2014 to September 2019. Featured findings were fever, enteritis, vomiting, anorexia, depression, dullness and/or weight loss. 163 of the cats were consulted in private veterinary clinics and 13 of them in Faculty of Ceyhan Veterinary Medicine. The animals' epidemiological status and clinically findings of fever, behavioral changes (insidious onset, depression), gastrointestinal (enteritis, vomitus, anorexia, weight loss, stomatitis, abdominal distension, ascites), circulatory (lymphadenopathy, anemia, icterus), cardio respiratory (dyspnea, abnormal heart and lung sounds), urinary, dermal, ocular lesions (uveitis, keratic precipitates, hyphema, iridocyclitis, chorioretinitis) and central nervous system (epileptic seizures, ataxia) symptoms were recorded. Blood sampling were done from the cephalic vein by the veterinarians. Haematological, biochemical and serological analyses were done to detect antibodies against FCoV and feline immunodeficiency virus (FIV) together with feline leukemia virus (FeLV) antigen. Additional FCoV antigen tests were done to stool samples. All analysis except FCoV IFAT

antibodies and protein analyses tests were carried out within an hour after sampling. IFAT tests and protein electrophoresis were carried out at an external private veterinary laboratory. The ill cats were evaluated during repeat visits for the progression monitoring of the infection.

Serological Tests

IFA tests; substrate slides consist of teflon-masked wells containing fixed feline kidney cells (Crandall), approximately 7-15% of which are infected with FIP Virus and contain the characteristic granular cytoplasmic fluorescence.

IFA and protein electrophoresis tests were done at a veterinary specific diagnostic laboratory. FCoV and *Feline Immunodeficiency Virus* (FIV) antibodies and *Feline Leucemia Virus* (FeLV) antigen tests; 176 samples were analysed by immunochromatographic lateral flow assay test for the detection of antibodies to FCoV (Bionote, Anigen, FCoV Ab) and FIV (Bionote, Anigen FIV Ab), and FeLV antigen (Bionote, FeLV Ag) according to the manufacturer instructions. The sensitivity (Se) and specificity (Sp) of the FCoV test compared to the reference immunofluorescence antibody test (IFA) were 96.0% and 97.9%, respectively, Se and Sp of the FeLV test versus virus isolation were 94.7% and 99.7%, respectively, and that of the FIV tests versus Western Blot were 96.8% and 99.6%, respectively. 168 serums IFA and protein electrophoresis tests were done by a private veterinary diagnostic laboratory. Serum giving fluorescence at a dilution above 1:20 was considered positive for antibodies against feline coronavirus as prescribed by the test kit manufacturer.

Postmortem Analyses

Dead cats in the study population were transferred to Çukurova University Ceyhan and Istanbul University Veterinary Faculty Virology departments with the approval of their owners within the scope of ongoing different projects regarding feline viral infections.

Stool Antigen Tests

Commercial immunochromatographic lateral flow assay test for the detection of FCoV antigen in the feces were used according to the manufacturer instructions. The detection limit of FCoV Ag is about $10^{4.5}$ TCID₅₀/ml. The sensitivity (Se) and specificity (Sp) were 96.15% and 95.65%, respectively.

Haematological and Biochemical Analyses

Haematological and histographical analyses were tested by veterinary specific auto analyzers to all samples. 168 samples comprehensive biochemistry analyzes were done by Vet-Scan (Abaxis) and 8 samples tests were done in private veterinary clinics. Haematological and biochemical tests included total white blood cell count (WBC), lymphocyte (LYM) and red blood cell (RBC) counts, hematocrit (HCT), hemoglobin (HGB), total protein (TP), albumin (Alb),

globulin (Glob), Alb/Glob ratio, alkaline phosphatase (ALP), alanine transaminase (ALT), amylase, total bilirubin (TBIL).

Rivalta Test

Ascites fluid from 19 cats was analyzed. The test solution prepared by 8 ml distilled water to which 1 drop of acetic acid (98%) is added and mixed thoroughly. 1 drop of the sampled effusion fluid is carefully layered on the surface of the testing solution.

Statistical Analyses

Data were analyzed using IBM SPSS statistics software. For clinical, hematological, and biochemical findings in FCoV infected cats, odds ratios and 95% confidence intervals were calculated. Biochemical and hematological results were categorized as being within (normal), above (high) or below (low) reference values (Villiers and Blackwood, 2005). Group statistics and independent samples tests were analysed by Levene's Test for equality of variances and t-test for equality of means. All variables were as shown in tables 1 to 4. For all comparisons, values of $P < 0.05$ were considered significant.

Results

Serological Results of FCoV, FIV, FeLV

164 (93.1%) of 176 FCoV Ab IFA positive cats were also positive to lateral flow Ab test (Figure 1). Despite positive IFA test results in 12 (7%) cats, the lateral flow test had negative results. Both IFA and lateral flow test results were negative at the first examinations of 2 cats with symptoms more likely to FIP infection; in contrast both were positive at 2 weeks later repeated tests. Although 1 cat's first IFA test was negative, the lateral test result was positive, and 2 weeks later the IFA test also was positive. In 22 (12.5%), 7 (3.9%) and 2 (1.1%) cats respectively, FIV antibody, FeLV antigen and feline morbillivirus (FmopV) RNA was detected together with FeCoV seropositivity. In 2 cats (1.1%) FeCoV, FIV and FeLV seropositivity was detected together. FCoV lateral flow antigen test was positive at all cats with FCoV antibody.

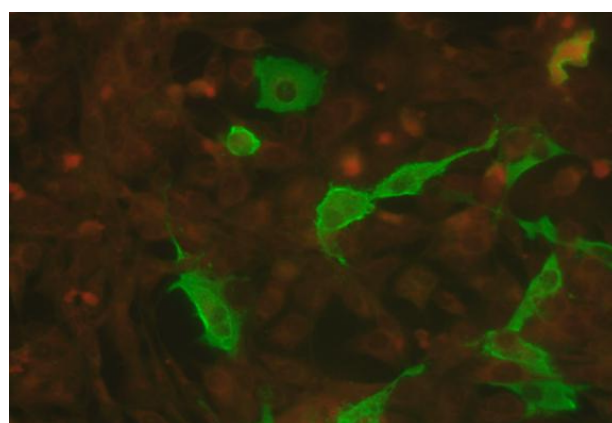


Figure 1. FCoV IFA antibody test positive result; appeared as bright granular fluorescence seen in the cytoplasm of infected cells

Epidemiological Data of Cats

Gender and age datas of the cats included in the study 91 (51.7%) male and 85 female (48.3%) and 109 (62%) were 0.3-2 years old age. Breed, ownership and habitat distribution were 129 (73.3%) are mixed, 47 (26.7%) pure breeds and 149 (84.7%) are house cats respectively. Amongst them 129 (73.3%) were living in multiple cat environments, and 86 (% 49.9) have outdoor access. The dead cats gender

and age distribution were 22 (55%) male and 18 female (45%), and 22 (62%) were between 0.3-2 years old age and 8 were (20%) older than 10 years old respectively. Breed and habitus distribution were 32 (80%) were mixed, 8 (20%) pure breeds, 31 (77.5%) household, 9 (22.5%) stray cats and 27 (67.5%) living in multiple cat environments and 21 (52.5%) have outdoor access respectively (Figure2).

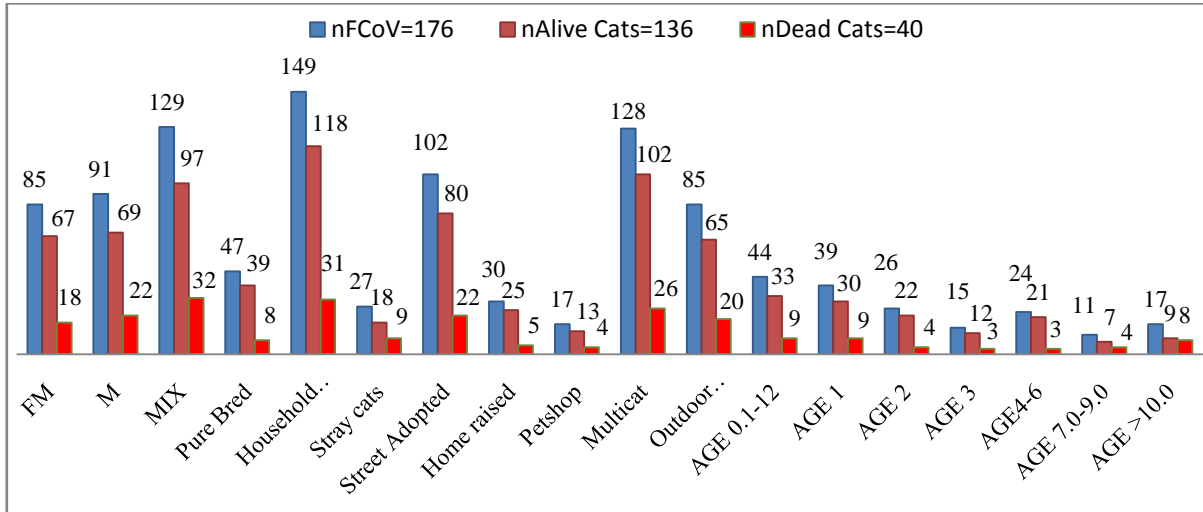


Figure 2. FCoV seropositive, alive and dead cats distribution according to gender, breed, age, habitat and origin

Clinicopathological Findings

In ill cats, fever 77% (136/176), depression and dullness 72% (126/176), diarrhoea 70% (124/169), weight loss 62% (109/176), vomiting 39% (69/176), respiratory tract infections 38% (67/176), ocular lesions 21% (37/176), abdominal enlargement 20% (36/176), as cites 11% (20/176), pleural effusion 10% (18/176) and neurological symptoms 5% (9/176) were observed. 125 (71%) cats were represented symptoms compatible with enteric form of the infection and, 102 cats (58%) had diarrhoea, mild fever, weight loss and dullness, and 23 cats had mild FECV infection without diarrhoea. 51 (29%) cats represented clinical signs that were

compatible with the wet and dry form of FIP infection. 40 of these cats (22,7%) died in spite of receiving veterinary treatment with high fever and other signs of infection that did not respond to standardized antibiotics and fluid-supplemented treatments. All dead cats represented weight loss and growth retardation, and other common symptoms of FIP infection such as abdominal distension, ascites, and pleural effusion were observed as 63% (25/40), 48% (19/40) and 45% (18/40), respectively. Depression and dullness 98% (39/40), 95% (38/40), 88% (35/40) vomiting, respiratory tract infection 80% (32/40) were other common findings. (Figures 3, 4 and 5).

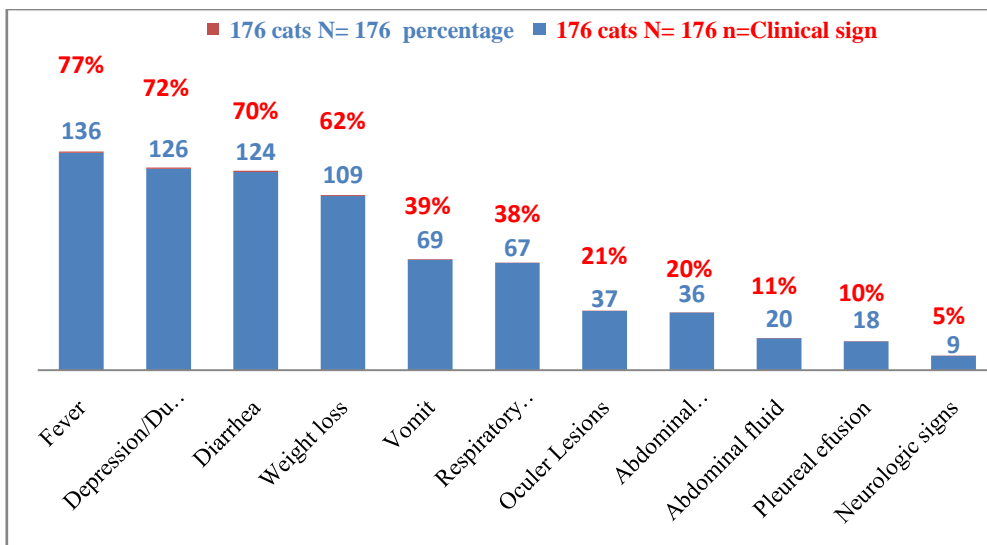


Figure 3. FCoV seropositive cats clinical signs percentage

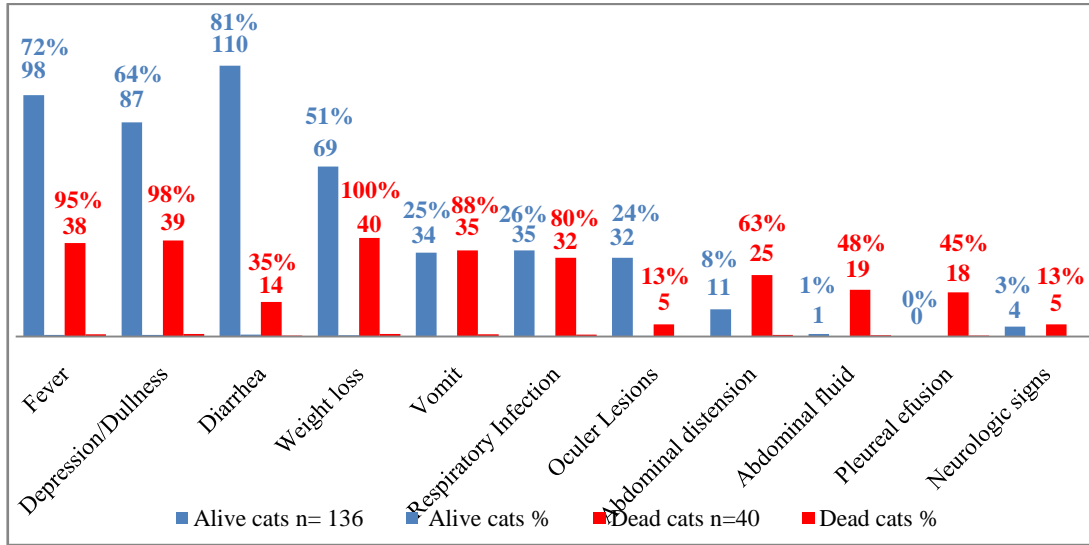


Figure 4. FCoV seropositive cats clinical signs percentage according to alive and dead status

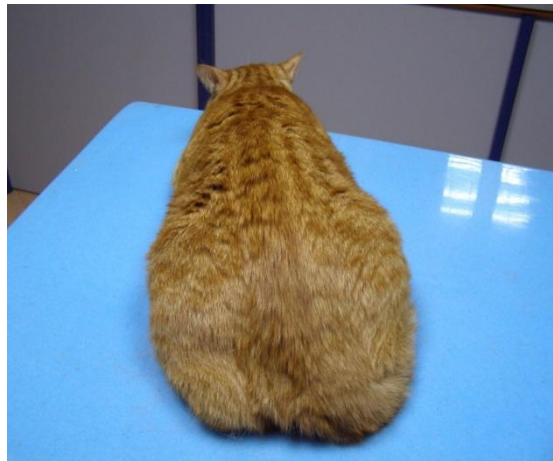

Figure 5. Depression and dullness of a FCoV and FIV seropositive cat

Postmortem Findings

Among the reported ones in this study, a total of 8 dead cats were investigated and some of the findings were previously published independently (Tekelioglu & Haligur

2016; Yilmaz & Tekelioglu et al. 2017). Of these, FCoV-RNA was detected in two FIP positive cats, and it was confirmed that 2 cats developed mixed FIP infection accompanied by neurological findings and 3 cats developed FIP in effusive form (Figures 6a and 6b).

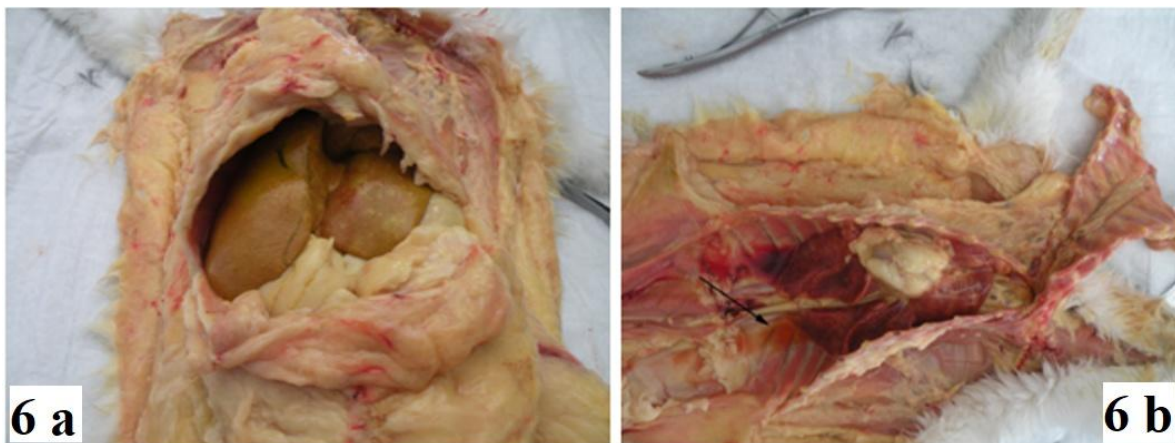


Figure 6a and 6b. Severe and diffuse icterus in subcutaneous tissues. Excessive fluid was accumulated in the pectoral cavity (arrow)

Ocular and Neurologic Signs

All cats examined during the study had additional findings as 21% (37/176) ocular lesions and 5% (9/176) neurological symptoms, and in cats that died, case death rates were 13% (5/40) of each (Figure 6). In the post mortem

examination severe and diffuse icterus in subcutaneous tissue, excessive accumulated fluid in the pectoral cavity, gray-white lesions in meninges were observed in cats (Figure 7a and 7b).

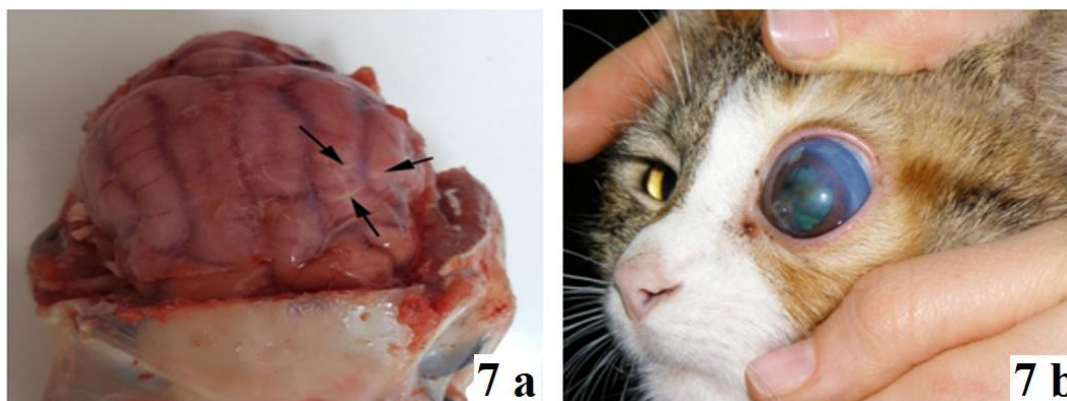


Figure 7a and 7b. Gray-white lesions in meninges (arrows). Unilateral glaucoma, uveitis and retinopathy; the cats were died in spite of the supportive treatment

Biochemical and Haematological Results

According to the biochemical and haematological tests results, the group and independent samples statistical analysis data according to gender and vital status (alive and dead) of the study population are shown in Tables 1 to 4. Data results were indicated that whole blood lymphocyte and hematocrit and serum ALB and ALT levels are significantly different ($P < 0.05$) according to gender-dependent group and independent sample test statistics

analysis (Table 1 and 3). The vital status-dependent group and independent samples test statistical analyses were indicated that Alb, Alb/Glob and Alp levels are significantly different ($P < 0.05$) at alive and dead status of the cats (Table 2 and 4). Abnormalities were particularly frequent in all cats with fever, depression/dullness and weight loss and 78% (69/88), 86% (76/88), 50% (44/88), 36% (32/88), 33% (29/88), 32% (28/88) of cats with these signs had high WBC, low A:G ratio, low HCT, high serum bilirubin levels, low RBC and low HGB, respectively.

Table 1. Haematological and biochemical results group statistical analyses according to gender

	Gender	N	Mean	Std. Deviation	Std. Error Mean
WBC	FM	85	20.42	9.82	1.06
	M	91	18.62	10.91	1.14
LYM	FM	85	12.29	17.39	1.88
	M	91	9.46	12.67	1.32
RBC	FM	85	8.65	3.49	.37
	M	91	8.44	2.90	.30
HGB	FM	85	11.72	4.27	.46
	M	91	11.58	3.50	.36
HCT	FM	84	34.86	11.70	1.27
	M	91	34.25	9.61	1.00
ALB ***	FM	85	2.61	.71	.07
	M	91	2.68	.63	.066
GLOB	FM	85	5.52	1.22	.132
	M	91	5.45	1.19	.125
Alb/Glob	FM	85	.51	.25	.027
	M	91	.52	.24	.025
TP	FM	85	8.18	1.11	.12
	M	91	8.26	1.13	.11
ALT	FM	85	79.52	55.41	6.01
	M	91	111.01	143.97	15.09
ALP	FM	85	46.97	56.62	6.14
	M	91	39.86	39.19	4.10
BIL	FM	85	.73	.93	.10
	M	91	.88	2.62	.27

*** Indicate values of $P < 0.05$ were considered significant. T-test groups = Gender ('FM' 'M'), variables= WBC, LYM, RBC, HGB, HCT, ALB, GLOB, ALB, GLO, TP, ALT, ALP, BIL / Criteria = CI (.95).

Table 2. Haematological and biochemical results group statistical analyses according to alive and dead status

	Dead	N	Mean	Std. Deviation	Std. Error Mean
WBC	Yes	40	21.30	10.66	1.68
	No	136	18.96	10.31	.88
LYM	Yes	40	13.26	18.50	2.92
	No	136	10.11	14.02	1.20
RBC	Yes	40	7.32	3.14	.49
	No	136	8.90	3.12	.26
HGB	Yes	40	9.48	3.88	.61
	No	136	12.28	3.66	.31
HCT	Yes	40	27.93	10.03	1.58
	No	135	36.50	10.04	.86
ALB ***	Yes	40	2.32	.56	.08
	No	136	2.74	.67	.05
GLOB	Yes	40	5.61	1.30	.20
	No	136	5.44	1.17	.10
Alb/Glob	Yes	40	.42	.18	.028
	No	136	.54	.25	.022
TP	Yes	40	7.99	1.31	.20
	No	136	8.29	1.05	.09
ALT	Yes	40	88.05	95.26	15.06
	No	136	98.08	115.79	9.92
ALP	Yes	40	74.2	84.08	13.29
	No	136	34.19	24.99	2.14
BIL	Yes	40	1.91	3.90	.61
	No	136	.49	.50	.043

*** Indicate values of P < 0.05 were considered significant. T-test groups = Dead ('YES' 'NO'), variables= WBC, LYM, RBC, HGB, HCT, ALB, GLOB, ALB, GLO, TP, ALT, ALP, BIL / Criteria = CI (.95).

Table 3. Haematological and biochemical results independent samples test statistical analyses according to gender

Levene's Test for Equality of Variances						t-test Equality of Means			95% Confidence Interval of the Difference	
Equal Variances	F.	Sig.	t	Df	Sig. (2-tailed)	Mean Difference	Std. Error Difference	Lower	Upper	
WBC	assumed	.14	.70	1.14	174	.25	1.79	1.56	-1.30	4.89
	not assumed			1.14	173.7	.25	1.79	1.56	-1.28	4.88
LYM ***	assumed	4.9	.02	1.23	174	.21	2.82	2.28	-1.67	7.33
	not assumed			1.22	152.8	.22	2.82	2.30	-1.72	7.38
RBC	assumed	2.8	.09	.42	174	.67	.20	.48	-.74	1.15
	not assumed			.42	163.8	.67	.20	.48	-.75	1.16
HGB	assumed	3.1	.080	.23	174	.81	.13	.58	-1.02	1.29
	not assumed			.23	162.7	.81	.13	.59	-1.02	1.30
HCT ***	assumed	4.8	.02	.37	173	.70	.60	1.61	-2.57	3.79
	not assumed			.37	161.02	.71	.60	1.62	-2.60	3.81
Alb	assumed	1.4	.23	-.66	174	.51	-.06	.10	-.26	.134
	not assumed			-.65	167.8	.51	-.06	.10	-.27	.13
Glob	assumed	.31	.57	.38	174	.70	.06	.18	-.29	.42
	not assumed			.38	172.4	.70	.069	.18	-.29	.43
Alb/Glob	assumed	.52	.46	-.11	174	.91	-.004	.03	-.07	.06
	not assumed			-.11	172.1	.91	-.004	.03	-.07	.06
TP	assumed	1.9	.16	-.47	174	.63	-.08	.16	-.41	.25
	not assumed			-.47	173.5	.63	-.08	.16	-.41	.25
ALT ***	assumed	14.1	.000	-1.89	174	.06	-31.49	16.66	-64.38	1.39
	not assumed			-1.93	117.6	.05	-31.49	16.24	-63.66	.67
ALP	assumed	.46	.49	.97	174	.33	7.11	7.30	-7.29	21.51
	not assumed			.96	148.2	.33	7.11	7.38	-7.49	21.71
BIL	assumed	.66	.41	-.49	174	.61	-.15	.30	-.74	.44
	not assumed			-.51	113.8	.60	-.15	.29	-.72	.42

*** Indicate values of P < 0.05 were considered significant. Variables = WBC, LYM, RBC, HGB, HCT, ALB, GLOB, ALB, GLO, TP, ALT, ALP, BIL / Criteria = CI (.95).

Table 4. Haematological and biochemical results independent samples test statistical analyses according to alive and dead status

Levene's Test for Equality of Variances						t-test for Equality of Means		95% Confidence Interval of the Difference		
Equal variances	F	Sig.	t	df	Sig. (2-tailed)	Mean Difference	Std. Error Difference	Lower	Upper	
WBC	assumed	.001	.98	1.25	17	.21	2.34	1.86	-1.34	6.03
	not assumed			1.20	62.05	.23	2.34	1.90	-1.44	6.14
LYM	assumed	4.95	.027	1.17	174	.29	3.15	2.72	-2.22	8.52
	not assumed			.96	52.87	.34	3.15	3.16	-3.19	9.49
RBC	assumed	.19	.72	-2.07	174	.006	-1.58	.56	-2.69	-.46
	not assumed			-2.79	63.43	.007	-1.58	.56	-2.71	-.45
HGB	assumed	.85	.35	-4.18	174	.000	-2.79	.66	-4.11	-1.47
	not assumed			-4.05	60.87	.000	-2.79	.69	-4.17	-1.41
HCT	assumed	.098	.75	-4.74	17	.000	-8.56	1.80	-12.13	-4.99
	not assumed			-4.74	63.95	.000	-8.56	1.80	-12.17	-4.95
ALB ***	assumed	4.24	.041	-3.61	174	.000	-.42	.11	-.65	-.19
	not assumed			-4.00	75.36	.000	-.42	.10	-.63	-.21
GLOB	assumed	.096	.75	.77	174	.442	.16	.21	-.26	.59
	not assumed			.73	59.09	.46	.16	.22	-.29	.62
Alb/Glob ***	assumed	12.38	.001	-2.94	17	.004	-.12	.04	-.21	-.04
	not assumed			-3.53	89.25	.001	-.12	.03	-.20	-.05
TP	assumed	.53	.46	-1.4	17	.13	-.30	.20	-.69	.09
	not assumed			-1.32	54.56	.192	-.30	.22	-.75	.15
ALT	assumed	.07	.79	-.50	17	.61	-10.03	20.05	-49.62	29.55
	not assumed			-.55	76.10	.580	-10.03	18.04	-45.96	25.89
ALP ***	assumed	51.89	.000	4.898	174	.000	40.08	8.18	23.93	56.23
	not assumed			2.97	41.04	.005	40.08	13.46	12.88	67.27
BIL	assumed	36.24	.000	4.14	174	.00	1.41	.34	.74	2.09
	not assumed			2.29	39.38	.027	1.41	.61	.16	2.67

* Indicate values of P < 0.05 were considered significant. Variables = WBC, LYM, RBC, HGB, HCT, ALB, GLOB, ALB, GLO, TP, ALT, ALP, BIL / Criteria = CI (.95).

In contrast amongst dead cats additional frequent abnormalities were ascites and pleural effusion and 73% (29/40), 90% (36/40), 63% (25/40), 48% (19/40), 45% (18/40), 55% (22/40), 45% (18/40), 40% (16/40) of cats with these signs had high WBC, low A:G ratio, abdominal distension, ascites, pleural effusion, low HCT and RBC, low HGB and high serum bilirubin levels, respectively. Ocular lesions and neurologic signs were observed of each 13% (5/40) at dead cats. Biochemical and haematological results were categorized as being within (normal), above (high) or below (low) reference values (Villiers and Backwood, 2005).

Protein electrophoresis results of 2 cats in the study population representing more likely signs of FIP infection (Figure 8a and 8b). Elevated γ -globulin levels (8b) as an indicator of the type of the infection and provides significant findings in differentiation the FIP disease and prognosis amongst FCoV seropositive cats at ante-mortem status (Kaneko et al., 2008).

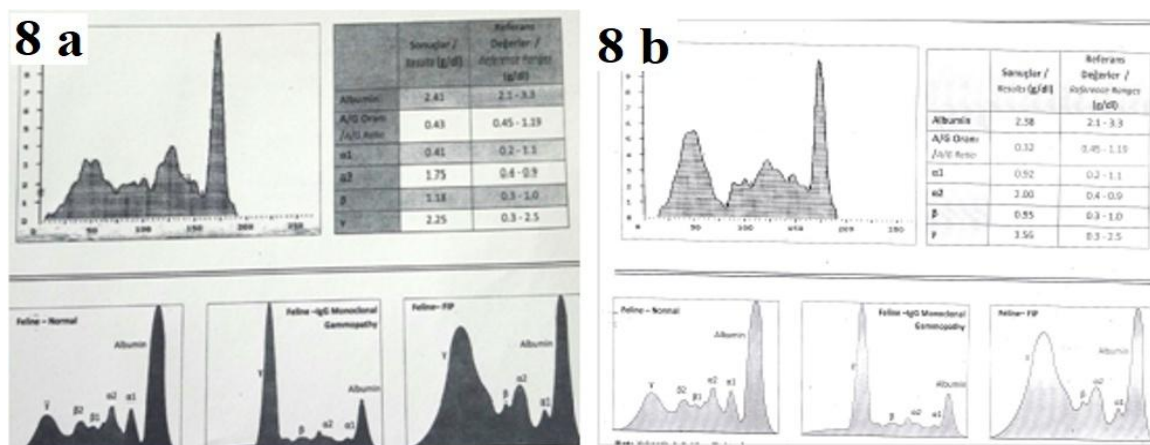


Figure 8a and 8b. 8a belongs to an alive FeCoV and FIV seropositive cat, represented chronic infection, low A/G: 0, 43 but normal γ -globulin levels. 8b, low A/G: 0,32 with elevated γ -globulin levels, belongs to a cat that died from FIP

Discussion

As the causative agent of the most complex diseases that a veterinarian may encounter, coronavirus infections remain their importance and increase their severity. This study mainly focused on the essentiality of following the diagnostic algorithms and its importance and guidance in distinguishing complex feline coronavirus infections and based on the analyses of 5 years data of 176 ill cats. In the differential diagnosis, following an algorithm that includes patient history, clinical findings, habitat information, serological tests, laboratory findings and tissue biopsy results is a recommended requirement (Addie et al., 2009; Sharif et al., 2010; Tsai et al., 2011; Pedersen, 2014; Tekelioglu et al., 2015).

Various risk factors associated with FCoV infection and FIP development have been reported and listed as gender, age, breed, multiple cat environment, street access and stress factors. In this study there is no gender dependent difference were observed (51,7% male and 48.3% female) amongst seropositive cats and similar results were previously reported (Addie et al., 2009; Sharif et al., 2010; Vogel et al., 2010; Myrrha et al., 2011; Tekelioglu et al., 2015). There is no known biological cause that supports gender-related susceptibility and resistance to FCoV, and differences between studies may be associated with living habitat and FCoV exposure. The breed was not found to be associated with FCoV seropositivity, the British shorthair breed had a higher ratio 45% (n=5/11) of representing FIP-like disease and dead status 50 % (n=4/8) among pure breed cats. Similar results were reported FCoV to be prevalent among British Shorthair in Japan and Australia (Taharaguchi et al., 2012; Worthing et al., 2012). In this study, FCoV was found to be significantly associated with age and FIP-like infection and habitat variables. Amongst them, 109 (62%) were 0.3-2 years old, 129 (73%) were living in multiple cat environments, and 86 (% 50) have outdoor access. A similar distribution was observed among deceased cats, 22 (62%) were 0.3-2 years old, and 8 were older than 10 (20%) and 27 (68%) lived in multiple cat habitats, and 21 (53%) cats had outdoor access. Our findings have similarities like others that the risk of FCoV infection increases in cats that share

the same cat litter, food and water containers with other cats, because the transmission occurs by the faecal-oral route, there is no direct or transplacental transmission (Addie et al., 2009; Sharif et al., 2010; Vogel et al., 2010; Ariani et al., 2019).

It was observed that 51 cats represented clinical symptoms and diagnostic results that were thought to be typically compatible with FIP disease, and 40 of them were died in spite of the veterinary treatment. Depression, dullness, progressive weight and appetite loss, vomiting, mild dyspnoea, fever not respond to antibiotic treatment and abdominal distension were common findings in these cats.

125 cats represented more likely the enteric form of the infection and all stools FCoV antigen test were positive. The statistical analyses data of this study were indicated that Alb, Alb/Glob and Alp levels are significantly different (P <0.05) at alive and dead status of the cats. Up to 12% of cats infected with FCoV have been reported to develop FIP disease (Addie et al., 2009; Sharif et al., 2010; Vogel et al., 2010; Pedersen 2014). As detailed in the results section, 8 (4,5%) of the deceased cats of which their post-mortem examinations were finalized and reported in this study as confirmed cases. Excessive fluid was observed in 6 cats and neurological signs in 2 cats. The most common neurological finding in these cats was epileptic seizures and ataxia. The most common ocular lesions in sick cats were uni or bilateral retinal changes and uveitis.

10,8% (n=19) of cats represented typical FIP findings compatible with the effusive and non effusive forms such as abdominal distension, ascites and pleural effusion, low hematocrit levels, positive Rivalta test result, increased γ -globulin and decreased albumin/globulin (A:G) ratio. As a supportive data to our results, the Rivalta's test were reported to have a high positive and very high negative predictive value for FIP as (86%) and (96%), respectively (Hartmann et al., 2003). This study indicated that γ -globulin levels provides significant findings in differentiation the FIP disease amongst FCoV seropositive cats at ante-mortem status and provides important assistance in determining the prognosis of the infection as a valuable diagnostic indicator

(Addie et al., 2009; Pedersen 2014; Taylor et al., 2011; Tekelioglu et al., 2015).

Post-mortem findings of this study as hepatitis, meningitis, nephritis, ocular and cardiopulmonary infections, granulomatous or pyogranulomatous lesions in various organs detected in deceased cats were indicated that feline coronavirus infections have a high mortality potential with multiple organ infections and similar findings have been reported by others. In cats that develop FIP, immune-mediated vasculitis and multiple organ failure develop due to damage to the blood vessels that feed the organs including the brain. The time between the occurrence of mutation and the emergence of clinical signs cannot be fully estimated. This period is known to be directly related to the response of the individual's immune system and can vary from a few weeks to 2 years (Kaneko et al., 2008; Addie et al., 2009; Vogel et al., 2010; Soma et al., 2013; Pedersen 2014; Yilmaz and Tekelioglu et al., 2017; Kanay and Ünver 2019).

In the haematological findings of our study, leukocytosis, erythrocytopenia, low hemoglobin and hematocrit levels, and moderate anemia were common among cats. Additionally, lymphocytopenia was observed in dead cats. Different haematological results have been reported in FCoV-infected cats (Hoskins 1993; Addie et al., 2009; Pedersen 2014; Giori et al., 2011; Cengiz and Gokce 2019). High bilirubin levels in 19 (37%) of 51 cats and 16 (40%) of 40 cats who died, indicating clinical signs compatible with FIP were detected. Of the deceased cats anemia were associated with low RBC and hematocrit in 22 (55%) cats and low hemoglobin level in 16 (40%) cats (Kaneko et al., 2008; Sharif et al., 2010; Tekelioglu et al., 2015; Yilmaz and Tekelioglu et al., 2017).

A significant difference in ALP level was found between the alive and dead cats ($P < 0.05$). It was thought that this might be related to high bilirubin level. The findings of our study suggest that the metabolism of bilirubin and its excretion into the biliary system are impaired in sick cats. The reason for elevated bilirubin levels in cats developing FIP is not clearly understood. Although high ALP and ALT activities do not increase as quickly as in hepatic necrosis as in other liver diseases, it may be a reflection of hepatic necrosis. In cats with FIP, bilirubin can sometimes increase without haemolysis, liver disease, or cholestasis (Addie et al., 2009; Sharif et al., 2010; Giori et al., 2011; Pedersen 2014; Hoskins 1993; Yilmaz and Tekelioglu et al., 2017; Cengiz and Gokce 2019).

Among the FCoV seropositive cats, FIV antibody in 22 cats (12,5%), FLV antigen in 7 cats (3,9%) and seropositivity against all three infections in 2 cats (1,1%) and FmopV RNA in 2 cats (1,1%) were detected. FCoV, FIV and FLV seropositivity results are similar to previous reports. Both cats, FCoV, FIV and FLV seropositive, died despite treatment with typical FIP symptoms. The multiple seropositivity against FCoV, FIV and FLV infections is a risk-increasing factor for developing FIP in diseased cats, and routine serological testing for all three diseases should be the essential protocol (Addie 2005; Oguzoglu et al., 2010; Tekelioglu et al., 2015).

Feline corona viruses have highly pandemic potential including FIP, especially in multi cat environments where young cats coexist (Wang et al., 2013). To date, numerous comprehensive studies on epizootiology and pathogenesis related to FIP infection have been made and have contributed to our further recognition of the disease. However, there are few studies and much more limited information about FCoV and FCoV-cat interactions. In experimental infections, cats have been reported to shed the virus through faeces for periods of 3 to 24 months (Pedersen et al., 2008; Desmarests et al., 2016). In this respect, it is thought that our study will contribute to the understanding of the disease by providing important information about the clinicopathology and seroepidemiology of FCoV infection. Preventing outdoor access of household cats and 3 or fewer cats living together in the same house reduces the risk of infection. It is now a common belief that all FCoV strains have the potential to cause FIP (Addie et al., 2009; An et al., 2011; Pedersen 2014; Hoskins 1993; Tekelioglu et al., 2015). In this study, upper respiratory tract infections were found in 67 (37%) cats and no detailed study on this subject was found. According to the evidence of the results, FCoV infections are thought to a potential causative agent of upper respiratory infections in cats. Detailed studies on this subject are carried out by other researchers (Cornell Vet 2020). As a result, it is thought that the findings obtained in the study contain useful information based on the clinicopathological, serological, haematological and biochemical results to contribute to the elucidation of the pathogenesis of complex feline corona virus diseases as FCoV and FIP.

COVID-19 and 'One Health' Approach

A novel coronavirus (nCoV) is a new strain that has not been previously identified in humans or animals, and did not emerge from any companion animal coronaviruses. The new virus was subsequently named the 'SARS-CoV-2 COVID-19' virus. The COVID-19 pandemic continues with the transmission of SARS-CoV-2 from person to person. Current information reveals that the infection originates from the *Rhinolophus* bat (Horseshoe Bat) source and is transmitted to humans, and there is no scientific evidence that humans are transmitted from other sources, including vectors. More detailed researches are needed to find the source, determine how the virus enters the human population and determine the potential role of animals in this disease (ABCD 2020; Rothan and Byrareddy 2020). Seven human coronaviruses (HCoVs) have been identified and all can cause respiratory system associated infections in humans (Corman et al., 2018; Cui et al., 2019).

Veterinary medicine has extensive past experiences and knowledge on evolution, seroepidemiology, clinicopathology and pathobiology about animal CoVs. FIPV and *avian infectious bronchitis virus* (IBV) have been known since 1960s. Perhaps the most important of what we have learned from the past experiences are that coronaviruses have high mutation ability, so that they can evolve and cross between species, and mutant strains can cause severe varied infections with variable tissue tropism (Decaro et al., 2020).

As some devastating examples, FCoV Serotype II arised from the recombination of FCoV serotype I with *canine coronavirus* (CCoV). In contrast three different CCoV have been identified in dogs (Lai and Holmes 2001; Pratelli 2008). Type I and type II are involved in group 1 and their evolution is associated with *feline coronavirus* type I and type II and CCoV type I is genetically more similar to FCoV type I than CCoV type II (Pratelli et al., 2003). A third *canine coronavirus* detected in the respiratory tract, CRCoV has <96.0% amino acid (aa) conservation in *bovine coronavirus* spike (S) protein in group 2 coronaviruses, which provides strong evidence that a new species crossover has been completed (Erles et al., 2003). Moreover swine transmissible gastroenteritis virus (TGEV), originated from CCoV (Lorusso et al., 2008). The well studied and detailed explained pathways of the cross-species transition indicate that the animal CoVs have an extraordinary natural ability to expand their host range.

The most important link that can be established between this study and COVID-19 is; FIP is an infection caused by mutated feline coronavirus. As a result of mutations between cats, a deadly virus and a severe disease appear. Its similarity with COVID-19 is that a cytokine storm occurs during this infection and requires a hyper inflammation treatment to reduce the lethal effect. The virus changes its biological behaviour, infecting monocytes, creating an intensive inflammatory infection called FIP and spreading to all organs, including the brain. The successful replication within the monocytes leads a lethal inflammation which results in pyogranulomas around blood vessels. As explained in the results of this study; in effusive form the duration is short, chaotic and resulting in death because there are lots of viruses in circulation and many blood vessels affected and finally, ascites, thoracic and pericardial effusions occurs due to the resulting of the leakage from damaged blood vessels. Contrarily, non-effusive FIP has a chronic course, the cat's immune system struggles more strongly with infection and fewer blood vessels are affected as a result. However, the prognosis is generally poor, quality of life decreases, and deaths occur in older ages, especially after the age of 10, after pyogranulomas occurring in different organs. The resemblances of pathogenesis of COVID-19 with FIP are characterized by the cytokine storm caused immunosuppression, increased interleukin (IL)-2, IL-6, IL-7, granulocyte-colony stimulating factor, interferon- γ inducible protein 10, monocyte chemo attractant protein 1, macrophage inflammatory protein 1- α , and tumour necrosis factor- α (Paltrinieri 2008; Mehta et al., 2020). Tocilizumab, the IL-6 receptor blocker monoclonal antibody, appears to be very effective in reducing the severity of SARS-CoV-2-induced pneumonia (Favalli et al., 2020).

Finally, many treatment protocols have been applied to control FIP disease and corticosteroids and antiviral agents has been used. After many years of research and some unsuccessful trials, two different classes of antiviral agents have been focused as protease inhibitors and nucleoside analogy that inhibit viral replication by blocking viral RNA transcription. GC376, a 3C-like protease inhibitor, has been reported to achieve significant success in the regression of symptoms and lesions, but only six of these animals

remained in remission for a long period after treatment in cats with natural FIP (Pedersen et al., 2019). The antiviral agent, which was recently developed and reported to be effective, was named GS-441524, is the main metabolite of nucleoside phosphate prodrug remdesivir. Studies have demonstrated that even when remdesivir is administered, GS-441524 is the predominant metabolite circulating in the serum due to the rapid hydrolysis of remdesivir prodrugs and subsequent phosphorylation. Long-term and repeated treatment was reported successful and additionally the same agent was reported as able to stop faecal shedding of FECV in naturally infected cats (Pedersen et al., 2018; Addie et al., 2020). Remdesivir, widely studied as a potential antiviral against COVID-19. This drug was shown to be more effective than lopinavir, which, similar to GC376, acts against the viral 3C-like protease (Baden and Rubin 2020).

For a vaccine that can be developed for COVID-19, animal CoVs can also represent excellent host models that can have a time-saving effect. There are coronavirus vaccines developed for animals. *Bovine coronavirus* (BCoV) for cattle and TGEV vaccines for pigs are available on market which are inactivated or modified live virus (MLV) vaccines and produced according to traditional protocols. It is also commercially available for PEDV prophylaxis in vector-based vaccines that express the spike protein, in addition to killed and MLV preparations (Gerdts and Zakhartchouk 2017; Saif 2020). CCoV vaccines are using parenterally. Although its systemic protection is high but mucosal protection remains low and therefore they have limited efficacy and are not protective against field strains for puppies (Pratelli et al., 2003; Pratelli et al., 2004). Licensed animal vaccines that can have a protective effect against coronaviruses that cause respiratory infections are IBV vaccines for chickens. They are produced for parenteral administration as intra ocular or intra nasal usage, so one of the most important problems encountered is that they do not adequately generate strong mucosal immunity associated mainly the immunoglobulin A (IgA). Even if mucosal immunity does not prevent infection, they can reduce viral shedding and severity of respiratory disease, and prevent the spread of infection, involving the kidney and reproductive system (Saif 2020). This data can be a valuable guide for SARS-CoV-2, which is primarily located in the respiratory system, causing the main disease there and affecting the enteric system and other organs less, after a limited viremia or systemic effect (Wong et al., 2020). Immunity occurring after natural infection with SARS-CoV-2 is not yet fully known. There are appropriate clinicopathological similarities for comparison between both infections. FCoVs generate a short-term immunity that does not protect against re-infections. Natural immunity to FCoV is poorly understood, but it is assumed to be cell mediated rather than antibody mediated. Circulating FCoV antibodies can actually increase disease progression. Mutations in the spike protein gene of FCoV, leads to the formation of hypervirulent and lethal FIPV. Researches to develop vaccines against FIP disease have many years of experimentations. There are promising and exciting developments among candidate vaccines and successful Phase III results have been announced. Despite all the

remarkable efforts to date, the fact that an effective vaccine has not been developed against FECV, FIPV and SARS-CoVs, gives an idea based on scientific experiences as to how difficult it is to develop the vaccine in COVID-19 (Addie et al., 2003; Brown et al., 2009; Addie et al., 2020; Jaimes et al., 2020). Perhaps as the most important problem to encountered, is an antibody-induced development (ADE) that triggered a more serious disease after virus challenge in vaccinated and immunized animals (German et al., 2004). A mechanism for ADE were reported for MERS-CoV previously that neutralizing antibodies bind to the spike protein and also triggered by antibody-mediated virus entry into macrophages via Ig Fc receptors, which might represent an obstacle to the development of SARS-CoV-2 specific vaccines (Wan et al., 2020).

Pet owners infected with COVID-19 have the potential to transmit the virus to their pets, and a small number of supportive case reports have been published. Therefore, the possibility of cats acting as fomites should be considered and avoiding close contact with cats and dogs living in the same homes as people infected with SARS-CoV-2 or showing symptoms of COVID-19 disease would be an important preventive action. Additional preventive actions may be required for those who have COVID-19 actively and need to continue to care for their pets during their illness. These are similar to which we follow in human to human contact and at social life. As a conspicuous result, preventive measures that eradicate FIP among cats are recommending to prevent the spread of COVID-19. Close contact with animals, kissing, sharing food, towels and clothing should be avoided, additionally washing hands with soap and water for at least 30 seconds before or after serving food and water will be effective actions. Case reports based on cats, dogs, tigers and lions infected with SARS-CoV-2 by COVID-19 infected owners and zookeepers is alerting us to act prudently to protect animals from SARS (ABCD 2020; Gollakner and Capua 2020; Info.Gov.HK. a,b,c., 2020; Chini 2020; Shi et al., 2020; WCS 2020; Zhang et al., 2020).

Social isolation to animals will also be useful until it is more widely understood how SARS-CoV-2 virus is transmitted from humans to animals and whether infected animals can transmit the virus to other animals and, perhaps, to humans again under natural conditions. Specifically animals living in houses, shelters, and zoos where COVID-19 infection is seen, should never be taken to another living place (ABCD 2020). Veterinarians and healthcare professionals should follow published guidelines on preventive measures and work in coordination with 'One Health'. In the early days of COVID-19 infection it has been focused on upper respiratory infections due to tissue tropism and virulence.

Coronaviruses have a high potential to cause acute and chronic infections affecting multiple organs in animals. CoVs have potentials to produce ocular diseases in animals and humans, ranging from anterior segment pathologies such as conjunctivitis and anterior uveitis to sight-threatening conditions such as retinitis and optic neuritis (Seah and Agrawal 2020). Neurological involvement has been reported in 1/3 of patients infected with COVID-19. The most common findings have been reported as dizziness, headache, consciousness and acute cerebrovascular disease.

SARS-CoV-2 is known to enter the nervous system through ACE2 receptors in neurons and glial cells (Serdaroglu and Serdaroglu 2020). COVID-19 and FCoV are not identical viruses taxonomically and recombination with other coronaviruses has been previously reported for FCoV and has been proposed for COVID-19. Although COVID-19 and FCoV differ in some pathogenic, clinical and pathological features, some well-known clinicopathological and immunopathogenic events in FIP in cats are also observed in people with COVID-19 (Paltrinieri et al., 2020). Identical infections have been observed in humans in the past 11 months since December 2019, similar to animals. One possible explanation for this sensitivity lies in the high degree of similarity between human and feline forms of the SARS-CoV-2 ACE2 receptor (Stout et al., 2020). These include permanent and recurrent upper respiratory tract infections, diarrhoea, and ocular and nervous system infections.

Conclusion

The author of this article describes the most important aspects of feline coronavirus and FIP infection and COVID-19, and the similarities and differences between these important diseases, based on scientific data of the cases he has clinically examined and followed-up for years. There is currently no effective vaccine developed for FIP, SARS-CoVs and COVID-19. An antiviral agent has been used for therapeutic purposes and reported to be effective against FIP, but its effectiveness for SARS-CoVs and COVID-19 has not been fully demonstrated and studies are ongoing. In particular, the clinicopathology and treatment modalities of feline coronavirus and COVID-19 infections are having similarities such as GS-441524 as the main metabolite of remdesivir prodrug and dexamethazone responses (NHI 2020), and both can cause resident and persistent infections in many organs, including the eyes and brain, of varying severity. This study demonstrates that FCoV infection in cats is a major health problem and following an algorithm for the differential diagnosis of the disease is essential, and should definitely begin with a comprehensive patient history. Detection of FCoV antibodies in the early stage can be useful to prevent the FCoVs spreading amongst feline population. Protective measures are a crucial requirement in multi cat habitats as shelters, breeding facilities, pet shops, and where more than 3 cats share the same house and where cats with outdoor access. FIP should be suspected in cats presenting with general malaise, including fever, depression, ascites, abdominal distension, diarrhoea, pleural effusion, post surgical stress and complications, and low A:G ratio that do not respond to antibiotic treatment. In accordance with the diagnostic algorithm, accurate diagnosis can be made by evaluating the results of serological, haematological and biochemical tests supported by the presence of clinical findings.

Veterinary medicine has many years of coronavirus experience. The data's of this study were also used in the philosophy of 'One Health' to better understand the etiology, pathogenesis and clinicopathology of coronaviral infections, and SARS-CoVs with COVID-19. Coronavirus infections of

other animals, especially those of cats, have been used by different scientists to better understand COVID-19 and comparative publications have been made within the 'One Health' approach (Menachery et al., 2015; Ramadan and sahib 2019; ABCD 2020; Decaro et al. 2020; Gollakner et al., 2020; NIAID 2020; Paltrinieri et al., 2020; Saif et al., 2020; Seah et al., 2020; Shi et al., 2020; Zhang et al., 2020). The coronavirus experience of veterinary medicine can guide future research in human medicine and shorten the time to achieve successful results in the development of immunogenic and safe vaccines and effective antiviral drugs. Successes and failures encountered in the prophylaxis and treatment of very complex animal CoV diseases such as FIP will guide COVID-19 and save time in the 'One Health' approach.

Acknowledgements

Author thanks Bilim Veterinary Diagnostic Laboratory for their cooperation and Dr. Kadir Yaşar Telatar for his helps in statistical analyses.

References

- Addie, D., Belák, S., Boucraut-Baralon, C., Egberink, H., Frymud, T., Hartmann, K., & Horzinek, M.C. (2009). Feline infectious peritonitis. ABCD guidelines on prevention and management. *Journal of Feline Medicine and Surgery*, 11(7): 594-604.
- Addie, D. (2005). Diagnosis of coronavirus and FIP in cats. *Proceeding of the NAVC*.
- Addie, D.D., Curran, S., Bellini, F., Crowe, B., Sheean, E., Ukrainchuk, L., & Decaro, N. (2020). Oral Mutian®X stopped faecal feline coronavirus shedding by naturally infected cats. *Research in Veterinary Science*, 130: 222-229.
- Addie, D.D., Mc Lachlan S.A., Golder M., Ramsey, I., & Jarrett, O. (2004). Evaluation of an in-practice test for feline coronavirus antibodies. *Journal of Feline Medicine and Surgery*, 6(2): 63-67.
- Addie, D.D., Schaap, I.A.T., Nicolson, L., & Jarrett, O. (2003). Persistence and transmission of natural type I feline coronavirus infection. *Journal of General Virology*, 84(10): 2735-2744.
- An, D.J., Jeong, H.Y., Jeong, W., Park, J.Y., Lee, M.H., & Park, B.K. (2011). Prevalence of Korean cats with natural feline coronavirus infections. *Virology Journal*, 8(1): 1-6.
- Almeida, A., Galdino, M.V., & Araújo Jr, J.P. (2019). Seroepidemiological study of feline coronavirus (FCoV) infection in domiciled cats from Botucatu, São Paulo, Brazil. *Pesquisa Veterinária Brasileira*, 39(2): 129-133.
- Baden, L.R., & Rubin, E.J. (2020). Covid-19—the search for effective therapy. *The New England Journal of Medicine*, 382: 1851-1852.
- Brown, M.A., Troyer, J.L., Pecon-Slattey, J., Roelke, E.M., & O'Brien, S.J. (2009). Genetics and pathogenesis of feline infectious peritonitis virus. *Emerging Infectious Diseases*, 15: 1445-1452.
- Cengiz, H.B., & Gökçe, H.I. (2019). Investigation of some hematological and biochemical parameters in cats with feline infectious peritonitis. *MAE Vet Fak Derg*, 4(2): 51-56.
- Cheng, V.C., Lau, S.K., Woo, P.C., & Yuen, K.Y. (2007). Severe acute respiratory syndrome coronavirus as an agent of emerging and reemerging infection. *Clinical microbiology reviews*, 20(4): 660-694.
- Chini, M. (2020). Coronavirus: Belgian woman infected her cat. *The Brussels Times*.
(<https://www.brusselstimes.com/all-news/belgium-all-news/103003/coronavirus-belgian-woman-infected-her-cat/>).
- Corman, V.M., Muth, D., Niemeyer, D., & Drosten, C. (2018). Chapter Eight - Hosts and Sources of Endemic Human Coronaviruses. *Advances in Virus Research*, 100: 163-188.
- COVID-19 treatment guidelines. 2020.
(<https://www.covid19treatmentguidelines.nih.gov/antiviral-therapy/>).
- COVID-19, MERS & SARS.
(<https://www.niaid.nih.gov/diseases-conditions/covid-19>).
- Cui, J., Li, F., & Shi, Z.L. (2019). Origin and evolution of pathogenic coronaviruses. *Nature Reviews Microbiology*, 17: 181-192.
- Decaro, N., Vito, M.V., Saif, L.J., & Buonavoglia, C. (2020). COVID-19 from veterinary medicine and one health perspectives: What animal coronaviruses have taught us. *Research in Veterinary Science*, 131: 21-23. <https://doi.org/10.1016/j.rvsc.2020.04.009>.
- Desmarets, L.M.B., Vermeulen, B.L., Theuns, S., Neto, N.C., Zeller, M., Acar, D.D. and Nauwycnk, J.H. (2016). Experimental feline enteric coronavirus infection reveals an aberrant infection pattern and shedding of mutants with impaired infectivity in enterocyte cultures. *Sci Rep*. 6:20022. Published online 2016 Jan 29. doi: 10.1038/srep20022
- Emmler, L., Felten, S., Matiasek, K., Balzer, J.H., Pantchev, N., Leutenegger, C. & Hartmann, K.. (2019). Feline Coronavirus With and Without Spike Gene Mutations Detected by Real-Time RT-PCRs in Cats With Feline Infectious Peritonitis. *J Feline Med Surg*. published online ahead of print, 1098612X19886671. doi:10.1177/1098612X19886671.
- Erles, K., Toomey, C., Brooks, H.W. & Brownlie, J. (2003). Detection of a group 2 coronavirus in dogs with canine infectious respiratory disease. *Virology*. 310: 216-223.
- Feline coronavirus and upper respiratory infections. Retrieved on May 31, 2020 from <https://www.vet.cornell.edu/research/awards/201805/feline-coronavirus-cause-upper-respiratory-infection-shelter-cats>
- Felten, S., Leutenegger, C.M., Balzer, H.J., Balzer, J.H., Pantchev, N., Mathisaek, K., Wess, G., Egberink H. & Hartmann, K. (2017). Sensitivity and specificity of a real-time reverse transcriptase polymerase chain reaction detecting feline coronavirus mutations in effusion and serum/plasma of cats to diagnose feline infectious peritonitis. *BMC Vet Res*. 13(1): 228. doi: 10.1186/s12917-017-1147-8.

- Gerds, V & Zakhartchouk A.(2017). Vaccines for porcine epidemic diarrhea virus and other swine coronaviruses. *Vet. Microbiol.* 206: 45-51.
- German, A.C., Helps, C.R., Harbour, D.A. (2004). Proceedings from the 2nd international FCov/FIP Symposium, Glasgow, 4-7 august 2002. *J. Feline Med. Surg.* 2004. FIP: a novel approach to vaccination: 119-124.
- Giori, L., Giordano, A., Giudice, C., Grieco, V. & Paltrinieri, S. (2011). Performances of different diagnostic tests for feline infectious peritonitis in challenging clinical cases. *J Small Anim Pract.* 52(3): 152-157.
- Gollakner, R. & Capua, I. (2020). Is COVID-19 the first pandemic that evolves into a panzootic? *Veterinaria Italiana* 2020, 56 (1), 11-12. doi:10.12834/VetIt.2246.12523.1
- Hartmann, K., Binder, C. & Hirschberger J. (2003). Comparison of different tests to diagnose feline infectious peritonitis. *J Vet Intern Med.* 17(6): 781-90.
- Hoskins, J.D. (1993). Coronavirus infection in cats. *Vet Clin North Am Small Anim Pract.* 23(1): 1-16.
- Jaimes, J.A., Millet, J.K., Stout, A.E., Andre, M.C. & Whittaker, G.R.(2020). A Tale of Two Viruses: The Distinct Spike Glycoproteins of Feline Coronaviruses. *Viruses.* 12 (1): 83.
- Kaneko, J.J., Harwey, J.W., Bruss, M. (2008). *Clinical biochemistry of domestic animals.* 6th edition, Academic Press, U.S.
- Kipar, A., Meli, M.L., Baptiste, K.E., Bowker, L.J. & Lutz, H. (2010). Sites of feline coronavirus persistence in healthy cats. *J Gen Virol.* 7(91): 1698-1707.
- Lai, M.M.C., & Holmes, K.V. (2001). Coronaviridae: the Viruses and their replication. In: Knipe D.M., Howley P.M., editors. *Fields virology.* 4th ed. Philadelphia: Lippincott Williams and Wilkins. pp: 1163-85.
- Lau, S.K. Woo, P.C., Yip, C., Fan, R.Y.Y., Huang, Y., Wang, M. & Yuen, Y.K. 2012). Isolation and characterization of a novel Betacoronavirus subgroup A coronavirus, rabbit coronavirus HKU14, from domestic rabbits. *Journal of Virology.* 86(10): 5481-5496.
- Lauzi, S., Straineri, A., Giordano, A., Luzzago, C., Zehender, G., Patrinieri, S. & Ebranati, E. (2020). Origin and transmission of Feline coronavirus type I in domestic cats from Northern Italy: a phylogeographic approach. *Vet Microbiol.* 244: 1-9.
- Li, C., Liu, Q., Kong, F., Guo, D., Zhai, M., Su, M. & Sun, D. (2018). Circulation and genetic diversity of Feline coronavirus type I and II from clinically healthy and FIP-suspected cats in China. *Transbound Emerg Dis.* 66(2): 763-775.
- Lorusso, A., Decaro, N., Schellen, P., Rottier, P.J.m., Buonavoglia, C., Haijema, B.J. & Groot, R.J. (2008). Gain, preservation, and loss of a group 1a coronavirus accessory glycoprotein. *J. Virol.* 82: 10312-10317.
- Lorusso, E., Mari, V., Losurdo, M., Lanave, G., Trotta, A., Dowgier, G., Bunoavoglia, D. & Decaro, N. (2019). Discrepancies between feline coronavirus antibody and nucleic acid detection in effusions of cats with suspected feline infectious peritonitis. *Res Vet. Sci.* 125: 421-424.
- Mehta, P., McAuley, D.F., Brown, M., Sanchez, E., Tattersall, R.S. & Manson, J.J. (2020). HLH Across Speciality Collaboration, UK. COVID-19: consider cytokine storm syndromes and immunosuppression. *Lancet pii:* S0140-6736 (20)30628-0.
- Menachery, V.D, Yount, B.L., Debbink, K., Agnihothrm, S., Gralinski, L.E., Plante, J.A. & Baric, R.S. (2015). A SARS-like cluster of circulating bat coronaviruses shows potential for human emergence. *Nat Med.* 21(12): 1508-1513.
- Myrrha, L.W., Silva, F.M., Peternelli, EF., Junior, A.S., Resende, M. & Almeida, M.R. (2011). The Paradox of Feline Coronavirus Pathogenesis: A Review. *Adv Virol.* 109849. doi: 10.1155/2011/109849.
- Myrrha, L.W., Silva, F.M.F., Vidigal, P.M.P., resend, M., Bressan, C.G., Fietto, R.L.J. & Almeida, M.R. (2019). Feline coronavirus isolates from a part of Brazil: insights into molecular epidemiology and phylogeny inferred from the 7b gene. *J Vet Med Sci.* 81: 1455-1460.
- Oğuzoğlu, T.Ç, Sahna, K.C, Ataseven, V.S. & Muz, D. (2010). Prevalence of feline coronavirus (FCov) and feline leukemia virus (FeLV) in Turkish cats. *Ankara Üniv Vet Fak Derg.* 57: 271-274.
- Paltrinieri, S. (2008). The feline acute phase reaction. *Vet. J.* 177: 26-35.
- Paltrinieri, S., Alessia, G., Angelica, S. & Stefania, L. (2020). Feline infectious peritonitis (FIP) and coronavirus disease 19 (COVID-19): Are they similar? *Transboundary and Emergin Dis.* doi: 10.1111/tbed.13856.
- Pedersen, N.C. (2014). An update on feline infectious peritonitis: Diagnostics and therapeutics. *Vet J.* 201(2): 133-141.
- Pedersen, N.C., Allen C.E. & Lyons L.A. (2008). Pathogenesis of feline enteric coronavirus infection. *J Feline Med Surg.* 10: 529-541.
- Pedersen, N.C, Kim, Y., Liu, H., Kankanamalage, G.C.A., Eckstarnd, C., Groutas, W., Bannasch, M., Meadows J.M. & Chang, K.O (2018). Efficacy of a 3C-like protease inhibitor in treating various forms of acquired feline infectious peritonitis. *J. Feline Med. Surg.* 20: 378-392.
- Pedersen NC, Lin H, Dodd K. & Pesavento, P. (2009). Significance of coronavirus mutants in feces and diseased tissues of cats suffering from feline infectious peritonitis. *Viruses.* 1: 166-184.
- Pedersen, N.C., Perron, M. & Bannasch, M. (2019). Efficacy and safety of the nucleoside analog GS-441524 for treatment of cats with naturally occurring feline infectious peritonitis. *J Feline Med Surg.* 21(4): 271-281.
- Pratelli, A, Martella, V., Decaro, N., Tinelli, A., Camero, M., cirone, F., Elia, G., Tempeta, M. & Buonavoglia, C. (2003). Genetic diversity of a canine coronavirus detected in pups with diarrhoea in Italy. *J Virol Methods.* 110: 9-17.
- Pratelli, A., Tinelli, A., Decaro, N., Cirone, F., Elia, G. & Roperto, S. (2003) Efficacy of an inactivated canine coronavirus vaccine in pups. *New Microbiol.* 26: 151-155.

- Pratelli, A., Tinelli, A., Decaro, N., Martella, V., Camero, M., Tempesta, M., Martini M.I., Carmichael, L.E. & Buonavoglia, C. (2004). Safety and efficacy of a modified-live canine coronavirus vaccine in dogs. *Vet. Microbiol.* 99: 43-49.
- Pratelli, A. (2008). Comparison of serologic techniques for the detection of antibodies against feline coronaviruses. *J Vet Diagn Invest.* 20(1): 45-50.
- Ramadan, N. & Shaib, H. (2019). Middle East respiratory syndrome coronavirus (MERS-CoV): A review. *Germs.* 9(1): 35-42.
- Rothan, H.A. & Byrareddy, S.N. (2020). The epidemiology and pathogenesis of coronavirus disease (COVID-19) outbreak. *J Autoimmunity.* 109: 1-4.
- Saif, L.J. (2020). Vaccines for COVID-19: perspectives, prospects, and challenges based on candidate SARS, MERS, and animal coronavirus vaccines. *Euro Med EMJ.* 2020; doi / 10.33590 / emj / 200324.
- SARS-Coronavirus (CoV)-2 and cats. Accessed date: Retrieved on May 31, 2020 from [https://www.info.gov.hk/gia/general/202003/19/P2020031900606.htm](http://www.abcdcatsvets.org/sars-coronavirus-2-and-cats/Seah, I., Agrawal, R. (2020). Can the Coronavirus Disease 2019 (COVID-19) Affect the Eyes? A Review of Coronaviruses and Ocular Implications in Humans and Animals. Ocul Immunol Inflamm. 2020: 1-5. doi: 10.1080/09273948.2020.1738501.</p>
<p>Serdaroğlu, E., Serdaroğlu, A. COVID-19 and Neurological Manifestations, COVID-19 ve Nörolojik Bulgular. (2020). <i>Türkiye Klinikleri J Med Sci.</i>doi: 10.5336/medsci.2020-76093.</p>
<p>Sharif, S., Arshad, S.S., Hair-Bejo, M., omar, A.R., Zeenathul, A.N. & Alazawy, A. (2010). Diagnostic methods for feline coronavirus: a review. <i>Vet Med Int.</i> 7: 28. doi: 10.4061/2010/809480.</p>
<p>Shi, J., Wen, Z., Zhong, G., Yang, H., Wang, C., Huang, B., Liu, R. & Bu, Z. (2020). Susceptibility of ferrets, cats, dogs, and different domesticated animals to SARS-coronavirus-2. <i>Science</i>, Apr 8: pii: eabb7015. doi:10.1126/science. abb7015.</p>
<p>Soma, T., Saito, N., Kawaguchi, M. & Sasai K. (2018). Feline coronavirus antibody titer in cerebrospinal fluid from cats with neurological signs. <i>J Vet Med Sci.</i> 80(1): 59-62.</p>
<p>Soma, T., Wada, M., Taharaguchi, S. & Tajima, T. (2013). Detection of ascitic feline coronavirus RNA from clinically suspected cats of feline infectious peritonitis. <i>The Journal of Veterinary Medical Science.</i> 75: 1389-1392.</p>
<p>Stout, A.E., Andre, N.M., Jaimes, J.A., Millet, J.K. & whittaker, G.R. (2020). Coronaviruses in cats and other companion animals: Where does SARS-CoV-2/COVID-19 fit? <i>Vet Microbiol.</i> 2020 Aug; 247: 108777. Published online 2020 Jun 23. doi:10.1016/j.vetmic.2020.108777.</p>
<p>Stranieri, A., Giordano, A., Paltrinieri, S., Glaudice, C., Cannito, V. & Lauzi, S. (2018). Comparison of the performance of laboratory tests in the diagnosis of feline infectious peritonitis. <i>J Vet Diagn Invest.</i> 30: 459-463.</p>
<p>Susanna, KP., Lau, P.C., Kenneth, S., Tsang, A.K.L., Fan, R.Y.Y., Luk, H.K.H. & Yuen, K.Y. (2015). Discovery of a Novel Coronavirus, China Rattus Coronavirus HKU24, from Norway Rats Supports the Murine Origin of Betacoronavirus 1 and Has Implications for the Ancestor of Betacoronavirus Lineage A. <i>Journal of Virology.</i> 89(6): 3076-3092.</p>
<p>Taharaguchi, S., Soma, T. & Hara M. (2012). Prevalence of feline coronavirus antibodies in Japanese domestic cats during the past decade. <i>J. Vet.Med. Sci.</i> 74: 1355-1358.</p>
<p>Taylor, S.S., Tappin, S.W., Dodkin, J.S., Papisoulitis, K. & Murphy, K.F. (2011). Serum Protein Electrophoresis in 155 Cats. <i>J Feline Med Surg.</i> 13(2): 74-80.</p>
<p>Tekelioglu, B.K. & Haligur, M. (2016). Feline Infectious Peritonitis In Naturally Infected Cats, A Clinical, Virological And Pathological Evaluation. 4th VetIstanbul Group Congress, 17-20. May. 2016, Sarajevo, Bosnia-Herzegovina.</p>
<p>Tekelioglu B.K., Berriatua, E., Turan, N., Helps, C.R., Kocak, M. & Yilmaz, H. (2015). A retrospective clinical and epidemiological study on feline coronavirus FCoV incats in Istanbul Turkey. <i>Pre Vet Med</i> 119(1-2): 41-47.</p>
<p>The Government of the Hong Kong Special Administrative Region - Press Releases. 2020a. Pet dog tests positive for COVID-19 virus. Retrieved on May 31, 2020 from <a href=)
- The Government of the Hong Kong Special Administrative Region - Press Releases. 2020b. Pet dog further tests positive for antibodies for COVID-19 virus. <https://www.info.gov.hk/gia/general/202003/26/P2020032600756.htm>
- The Government of the Hong Kong Special Administrative Region - Press Releases. 2020c. Pet cat tests positive for COVID-19. <https://www.info.gov.hk/gia/general/202003/31/P2020033100717.htm>
- Tsai, H.Y., Chueh, L.L., Lin, N.C. & Su, L.B. (2011). Clinicopathological findings and disease staging of feline infectious peritonitis: 51 cases from 2003 to 2009 in Taiwan. *J Feline Med Surg.* 13(2): 74-80.
- Villiers, E., Blackwood & L. (Eds.). (2005). *BSAVA Manual of Canine and Feline Clinical Pathology.* British Small Anim. Vet. Assoc., Gloucester, UK.
- Vogel, L., Van der Lubben, M. & te Lintelo, E.G. (2010). Pathogenic characteristics of persistent feline enteric coronavirus infection in cats. *Vet Res.* 41(5): 71.
- Wan Y, Shang J, Sun S, et al. (2020). Molecular mechanism for antibody-dependent enhancement of coronavirus entry. *J. Virol.* 94(5): Pii: e02015-19.
- Wang, Y.T., Su, B.L., Hsieh, L.E. & Chueh, L.L. (2013). An outbreak of feline infectious peritonitis in a Taiwanese shelter: Epidemiologic and molecular evidence for horizontal transmission of a novel type II feline coronavirus. *Veterinary Research* 44(1): 57. doi:10.1186/1297-9716-44-57.
- WCS Newsroom. A tiger at Bronx zoo tests positive References for COVID-19; The tiger and the zoo's other cats are doing well at this time. Retrieved on May 31, 2020 from <https://newsroom.wcs.org/News-Releases/articleType/ArticleView/articleId/14010/A-Tiger-at-Bronx-Zoo-Tests-Positive-for-COVID-19-The-Tiger-and-the-Zoos-Other-Cats-Are-Doing-Well-at-This-Time.aspx> Wong, S.H., Lui, R.N. & Sung, J.J. (2020). Covid-19 and the digestive system. *J.*

Gastroenterol. Hepatol. First published: 25.03.2020
<https://doi.org/10.1111/jgh.15047>

World Health Organisation (WHO).
<https://www.who.int/emergencies/novel-coronavirus-2019>

Worthing, K., Wigney, D., Dhand, N.K, Fawcett, A., McDonagh, P., Malik, R. & Norris, M.J. (2012). Risk factors for feline infectious peritonitis in Australian cats. *J. Feline Med. Surg.* 14: 405-412.

Yanga, Y., Peng, F., Wang, R., Guan, K., Jiang, T., Xu, G., Sun, J. & Chang, C. (2020). The deadly coronaviruses: The 2003 SARS pandemic and the 2020 novel coronavirus epidemic in China. *J Autoimmun.* 2020; 109: 102434. doi:10.1016/j.jaut.2020.102434

Yilmaz, H., Tekelioglu, B.K., Aydin, Y., Bamac, O.E., Ozturk, G.Y., Cizmecigil, U.Y., Altan, E., Aydin, O., Yilmaz, A., Berriatua, E., Helps, C.R., Richt, J.A. & Turan, N. (2017). Frequency, Clinicopathological Features and Phylogenetic Analysis of Feline Morbillivirus in Cats in Istanbul, Turkey. *J Feline Med Surg.* 19(12): 1206-1214.

Zhang, Q., Zhang, H. & Huang, K. (2020). SARS-CoV-2 neutralizing serum antibodies in cats: a serological investigation [Internet]. Wuhan, 2020. <https://www.biorxiv.org/content/10.1101/2020.04.01.021196v1.full.pdf>.